YOLO–Based tumor detecting for brain MRI images

Author:Ayham Obeidat,Omar Jabour,Layan Nofal
University of Jordan

19 May 2025

Abstract

Recent advancements in image processing and computer vision have brought significant transformations in healthcare technology, leading to significant improvements in diagnosis accuracy, cost-effectiveness, and time efficiency. Magnetic Resonance Imaging (MRI) is employed by the radiologist for its remarkable ability to detect even the most subtle brain abnormalities. This study considers a comprehensive analysis of the two prominent object identification frameworks, YOLOv5 YOLOv8 and yolov11, . The brain tumor dataset encompasses three distinct classes, including meningiomas, gliomas and pituitary tumors. The results for the yolov11 model demonstrate high overall detection performance with a mean average precision (mAP@0.5) of 0.916 across all classes. While meningioma and pituitary tumors achieved outstanding precision and recall scores (above 0.96), the glioma class consistently lagged behind, with a lower F1 score and mAP of 0.817. The Precision-Recall Curve and F1-Confidence Curve highlighted this disparity, indicating that glioma cases were often misclassified or assigned lower confidence scores.The results for the yolov8 model demonstrate excellent overall detection capability, achieving an mAP@0.5 of 0.924, with peak F1 score of 0.89 at a confidence threshold of 0.435. Class-wise evaluation shows that meningioma (0.976) and pituitary tumors (0.967) achieve high average precision and recall. However, glioma lags behind, with a noticeably lower AP of 0.829.The results highlight that YOLOv5 performs strongly overall, achieving a mean average precision (mAP@0.5) of 0.919, and a peak F1 score of 0.90 at a confidence threshold of 0.479. Both meningioma (AP = 0.974) and pituitary (AP = 0.956) classes exhibit excellent precision and recall across all confidence levels. However, the glioma class remains a bottleneck, with a lower AP of 0.827. To underscore the novelty of the approach, we will bw compare the three versions of YOLO propsed in this paper, seeing who performs best.

1 Introduction

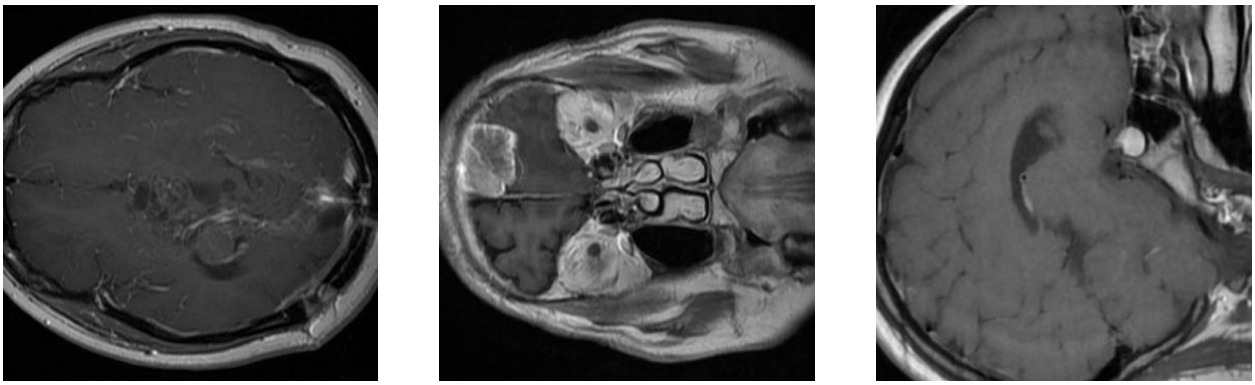

(a) photo of brain suspecting glioma tumor

(b) photo of brain suspecting meningioma tumor

(c) photo of brain suspecting pituitary tumor

Figure 1: MRI scans of the brain checking for Brain Tumor

1.1 Background

brain cancer is a widespread illness that result in numerous casulities each year,even in developed contries, in the united states the death toll is particulary alamring, with aproximitly 20,000 lives are lost to this disease[1]. cancer happens when the cells start growing in a uncontrolled rates and spreads within the body,However in cases where this well-organized process fails, abnormal or damaged cells can proliferate inappropriately. These cells can manifest as tissue masses called tumors. Primary brain tumors, for instance, originate in the brain and typically remain localized there [2], [3].On the other hand, secondary brain tumors begin elsewhere in the body and subsequently spread to the brain [4].

tumors can be classified into two types malignant and benign. malignant tumors can spread into neighboring tissues and metastasize, forming new tumors in distant body parts. in contrast, benign tumors do not spread to nearby tissues and lack the capacity to metastasize,benign tumors once removed they do not regenerate unlike malignant tumors, although benign tumor do not spread they still cause life-threatening risks. Human brain is a crucial for controlling actions and decision-making, acting as the central hub of the nervous system. Protecting it from harm is essential and among potential threats, tumors are a significant concern. Specific types of brain tumors, such as meningioma, glioma, and pituitary tumors, result from abnormal cell growth. Meningiomas typically develop in the thin membranes surrounding the brain and are primarily benign [5]. Despite their benign nature, they still present a life-threatening disease that directly impacts human life. Meningiomas, which make up 36.1% of all primary tumors, tend to cluster around the brain's outer and upper contours. The meninges are the three layers of tissue that cover and protect the brain and spinal cord, and these growths emerge as bumps there. Meningioma may be diagnosed based on its anatomical location, form, and cellular appearance. These tumors develop slowly and might cause serious side effects, including convulsions and vision loss. However,

gliomas are tumors that develop from the brain's glial cells rather than its neurons. They comprise a large subset of tumors with a wide range of symptoms and danger levels. In addition, the pituitary glands at the base of the skull are surrounded by cells, and tumors may form as aberrant masses there. Due to their closeness to the pituitary glands, which play a vital role in regulating hormone synthesis and release, these tumors can affect many biological systems. The ability to successfully prevent and treat brain tumors depends on thoroughly understanding the disease's many phases. Radiologists have used various imaging modalities, such as X-ray, Magnetoencephalography (MEG), Computed Tomography (CT), Ultrasound, Electroencephalography (EEG), and Magnetic Resonance Imaging (MRI), to examine brain tumors and aid in accurate diagnosis and selection of appropriate treatment in recent years. Primary brain tumors vary significantly in size, location, and other features, making early diagnosis difficult. Accurate visualization of tumors by non-invasive imaging methods relies on the absorption characteristics of tissues, making it necessary to precisely delineate absorption rates for efficient tumor imaging [6]. When comparing various imaging options, magnetic resonance imaging (MRI) stands out as the gold standard because it can provide information about the brain in both healthy and diseased states. In the event of anomalies, it aids in pinpointing the precise tumor type [7]. However, analyzing MRI scan results requires meticulous observation and a high level of proficiency, making it impossible for an ordinary person to perform. Unfortunately, some hospitals and healthcare centers still lack the expertise to meet these requirements, further contributing to the lengthy diagnostic process [8].The rapid advancements in machine learning and computer vision have given rise to power solutions known as Convolutional Neural Networks (CNNs). These cutting-edge models have successfully addressed complex Computer-Aided Diagnosis (CAD) problems, encompassing recognition, classification, segmentation, and even detection. but as powerful they are they need stron computional power and the lighter ariants of CNN classification models have inherent limitations when pinpointing the tumor's exact location precisely.However, the You-Only-Look-Once (YOLO) algorithm has gained considerable attention due to its exceptional object detection system and employs single unified neural network. This algorithm revolutionized object detection by treating it as a regression problem, estimating bounding box coordinates and class probabilities directly from pixel-level information. It enables the simultaneous prediction of multiple bounding boxes and class probabilities, having higher performance in terms of both speed and accuracy. As a result, it has found widespread application in the medical field, such as its ability to accurately categorize and locate abnormalities in brain images, as demonstrated in this study.

1.2 Problem Statement

MRI images which are the one of the best methods for scanning for brain tumors , researchers face the challenge of developing an alogrithm that can automaticly chracterize the status of patients suspecting one of three tumors(glioma,meningioma,pituitary), the accuracy needs to be high and extreme due to the importance of poeple's lives.

1.3 Objectives

On that basis, the aim of this research work focuses on detecting tumors from MRI images, classified by an expert reader, with three possible outputs: glioma,meningioma, we propse three variant of YOLO deep learning models, namely YOLOv5,YOLOv8, and YOLOv11 that provides a more efficient solution for segmenting and classifying brain tumors from MRI scans.The evaluation of the models are accomplished through F1-Confidence Curve,Precision-Recall Curve,Recall-Confidence Curve, Precision-Confidence Curve and the usage of a confusion matrix graph.

1.4 Scope

The contribution of this project is to propose a YOLO model with high accuracy to be a reliable source for detecting tumors and putting bounding boxes with high confidence level.

(a) glioma tumor (b) meningioma tumor (c) pityitary tumor

Figure 2: bounding boxes surrounding each tumor in the brain

2 Related Work

2.1 Research Papers Comparison

Study	**Model / Method**	**Dataset**	**Gap**
Application of MRI image segmentation algorithm for brain tumors based on improved YOLO	YOLOv5s algorithm	3439 MRI images of meningioma and glioma from Kaggle	Limited class coverage (no pituitary)
A Computer-Aided Diagnosis of Brain Tumors Using a Fine-Tuned YOLO-based Model with Transfer Learning	YOLOv4	3064 MRI images from Nanfang Hospital (2005–2010)	No comparison with other YOLO versions
This work	YOLOv5s, YOLOv8n, YOLOv11n (custom)	3064 MRI images (glioma, meningioma, pituitary)	Introduces **custom YOLOv11**, addresses class imbalance, and compares models under consistent conditions

Table 1: Comparison of Brain Tumor Detection Studies Using YOLO Variants

Our project stands out by comparing YOLOv5, YOLOv8, and a custom YOLOv11 model under consistent conditions, providing a fair and reliable evaluation. We also addressed class imbalance and explored preprocessing strategies. Unlike many studies, we introduced a custom model and performed a detailed comparison, making our work more targeted and insightful

3 Methodology

This project seeks to assess and compare the effectiveness of three object detection models (YOLOv5, YOLOv8, and YOLOv11) in detecting brain tumors from medical images. The approach is organized into the following stages:

3.1 Dataset Preparation

The dataset used in this study consists of three brain tumor classes: glioma, meningioma, and pituitary. The data was organized into a standard YOLO-compatible structure, with

three main directories: train, val, and test. Each of these directories contains two subfolders: images/ (holding the input images) and labels/ (containing corresponding .txt annotation files). A stratified split was applied to preserve class distribution across the sets, resulting in 2144 images for training, 612 for validation, and 308 for testing. The annotations in the labels/ folders follow the YOLO format, where each .txt file contains one or more lines specifying the class index and normalized bounding box coordinates (center x , center y, width, height). A data.yaml file was created to specify the dataset paths and class names, enabling seamless integration with YOLOv5, YOLOv8, and YOLOv11 training pipelines.

3.2 Preprocessing

The original images were 260×260 pixels. Since YOLO models work best with 640×640 pixel images, all images were resized to that size. We also made sure that every image had a matching label file with the correct class and bounding box information in YOLO format. The dataset was arranged in the YOLO folder format, with separate images and labels folders inside the train, val, and test folders. These steps helped prepare the data properly for training YOLOv5, YOLOv8, and YOLOv11 models.

3.3 Model Training

- Three YOLO models were trained independently:
  - YOLOv5s
  - YOLOv8n
  - YOLOv11n
- Each model was trained for 50 epochs using:
  - Batch size: 16
  - Optimizer: Automatic selection
  - Device: GPU
- Training was performed using the native training scripts of each version.
- Custom data.yaml files were created to specify class names and dataset paths

3.4 Evaluation

Each model was evaluated using the validation and test sets. Performance metrics such as precision, recall, mAP50, and confusion matrices were collected. These metrics were used to compare the detection accuracy and generalization of each YOLO version.

Model	**Precision**	**Recall**	**mAP50**	**mAP50-95**
yolov5	0.924	0.88	0.919	0.693
yolov8	*0.891*	*0.883*	*0.924*	*0.711*
yolov11	*0.917*	*0.856*	*0.922*	*0.715*

Table 2: Performance comparison of YOLO models

3.5 Visualization

Detection results were visualized on test images to qualitatively assess model outputs. Additionally, confusion matrices and precision-recall curves were generated for each model to help interpret classification performance.

3.6 Experiment

To address class imbalance and potentially improve generalization, we conducted an experiment combining two preprocessing strategies:

1. Undersampling the pituitary class (the most dominant class) to match the count of glioma,
2. Applying data augmentation such as flipping, rotation, and noise injection.

After retraining the YOLOv11 model using this modified dataset, we evaluated its performance and compared it to the original model (trained on the full, imbalanced dataset without augmentation).

Results:

- F1 Score: Slight drop in overall F1, especially for glioma, which went from ˜0.74 to ˜0.70.
- Precision & Recall: Both declined slightly for glioma, suggesting the changes may have introduced more false positives and false negatives.
- mAP@0.5: Remained unchanged (˜0.896), indicating localization performance was preserved.
- Confusion Matrix: Increase in background-to-glioma misclassifications, possibly due to noisy augmentations or reduced representation of pituitary features.

4 Discussion

4.1 Interpretation of Results

YOLOv8 achieved the highest detection accuracy (mAP@0.5 = 0.924), closely followed by YOLOv5 and YOLOv11. While all models excelled in detecting meningioma and pituitary tumors, glioma detection remained consistently challenging

4.2 Strengths

YOLO models provided rapid and accurate tumor detection, particularly excelling in straightforward cases like meningioma and pituitary tumors, demonstrating their practical value in clinical diagnostics.

4.3 Weaknesses / Error Analysis

Glioma detection proved problematic across all YOLO versions, with frequent misclassifications and lower confidence scores, likely due to glioma's ambiguous imaging characteristics.

4.4 Practical Implications

Implementing YOLO models, especially YOLOv8, could significantly enhance clinical efficiency in preliminary screenings. However, glioma detections should be carefully verified by radiologists to ensure diagnostic accuracy.

5 Conclusion and Future Work

5.1 Summary of Findings

YOLOv8 outperformed other models, offering the highest accuracy in tumor detection, yet struggled with glioma cases.

5.2 Contributions

This project demonstrated YOLOv8's efficacy for clinical diagnostics, highlighting both model strengths and areas needing improvement.

5.3 Limitations

Glioma detection remains the primary limitation, impacted by ambiguous imaging features and class imbalance issues.

5.4 Future Improvements

Future efforts should focus on refining glioma detection through enhanced dataset augmentation and targeted model optimization strategies.

References

1. Key Statistics for Brain and Spinal Cord Tumors, May 2023,

2. S. Lapointe, A. Perry and N. A. Butowski, "Primary brain tumours in adults", Lancet, vol. 392, no. 10145, pp. 432-446, Aug. 2018.

3. E. I. Zacharaki, S. Wang, S. Chawla, D. Soo Yoo, R. Wolf, E. R. Melhem, et al., "Classification of brain tumor type and grade using MRI texture and shape in a machine learning scheme", Magn. Reson. Med., vol. 62, no. 6, pp. 1609-1618, Dec. 2009.

4. J. Liu, M. Li, J. Wang, F. Wu, T. Liu and Y. Pan, "A survey of MRI-based brain tumor segmentation methods", Tsinghua Sci. Technol., vol. 19, no. 6, pp. 578-595, Dec. 2014.

5. J. Amin, M. Sharif, A. Haldorai, M. Yasmin and R. S. Nayak, "Brain tumor detection and classification using machine learning: A comprehensive survey", Complex Intell. Syst., vol. 8, no. 4, pp. 3161-3183, Aug. 2022.

6. Z. N. K. Swati, Q. Zhao, M. Kabir, F. Ali, Z. Ali, S. Ahmed, et al., "Brain tumor classification for MR images using transfer learning and fine-tuning", Computerized Med. Imag. Graph., vol. 75, pp. 34-46, Jul. 2019..

7. J. Watts, G. Box, A. Galvin, P. Brotchie, N. Trost and T. Sutherland, "Magnetic resonance imaging of meningiomas: A pictorial review", Insights Imag., vol. 5, no. 1, pp. 113-122, Feb. 2014.

8. G. Litjens, T. Kooi, B. E. Bejnordi, A. A. A. Setio, F. Ciompi, M. Ghafoorian, et al., "A survey on deep learning in medical image analysis", Med. Image Anal., vol. 42, pp. 60-88, Dec. 2017.

9. Application of MRI image segmentation algorithm for brain tumors based on improved YOLO https://www.frontiersin.org/journals/neuroscience/articles/10.3389/fnins.2024.1510175/full

10. A Computer-Aided Diagnosis of Brain Tumors Using a Fine-Tuned YOLO-based Model with Transfer Learning https://koreascience.kr/article/JAKO202009135419641.page